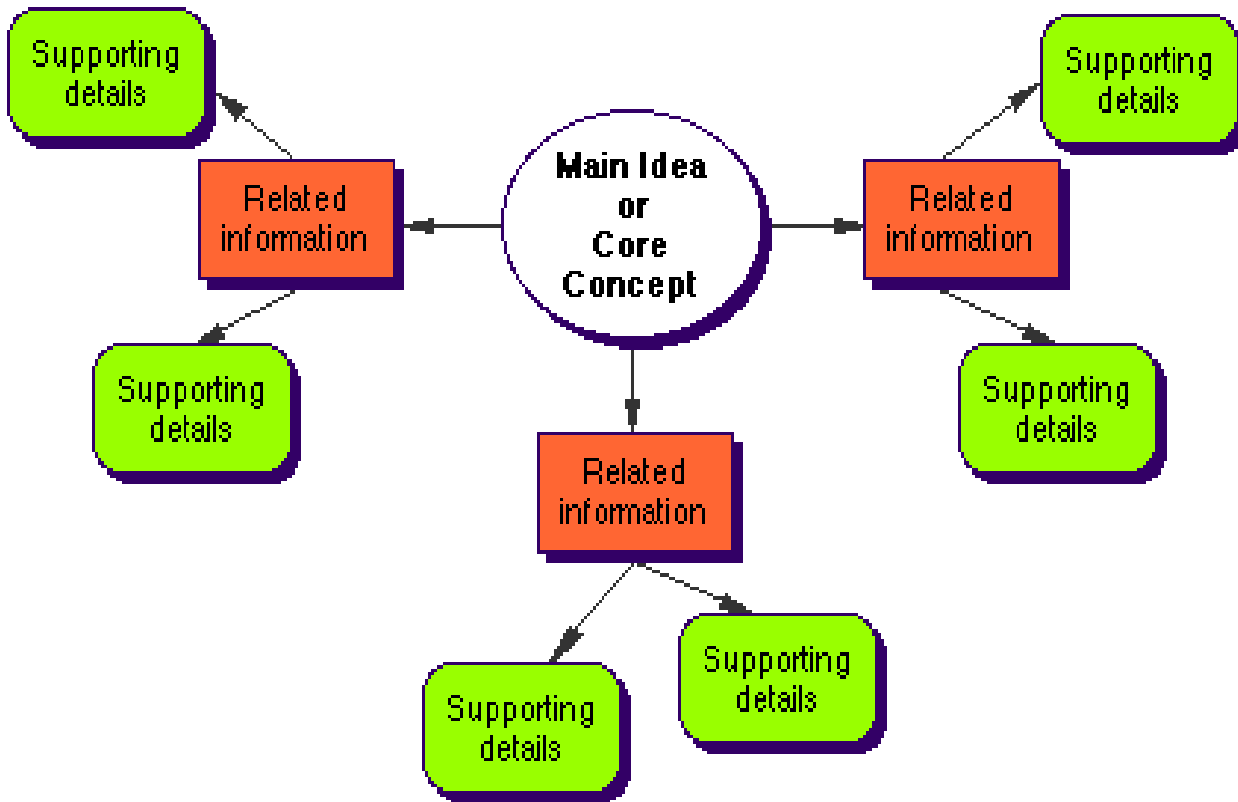
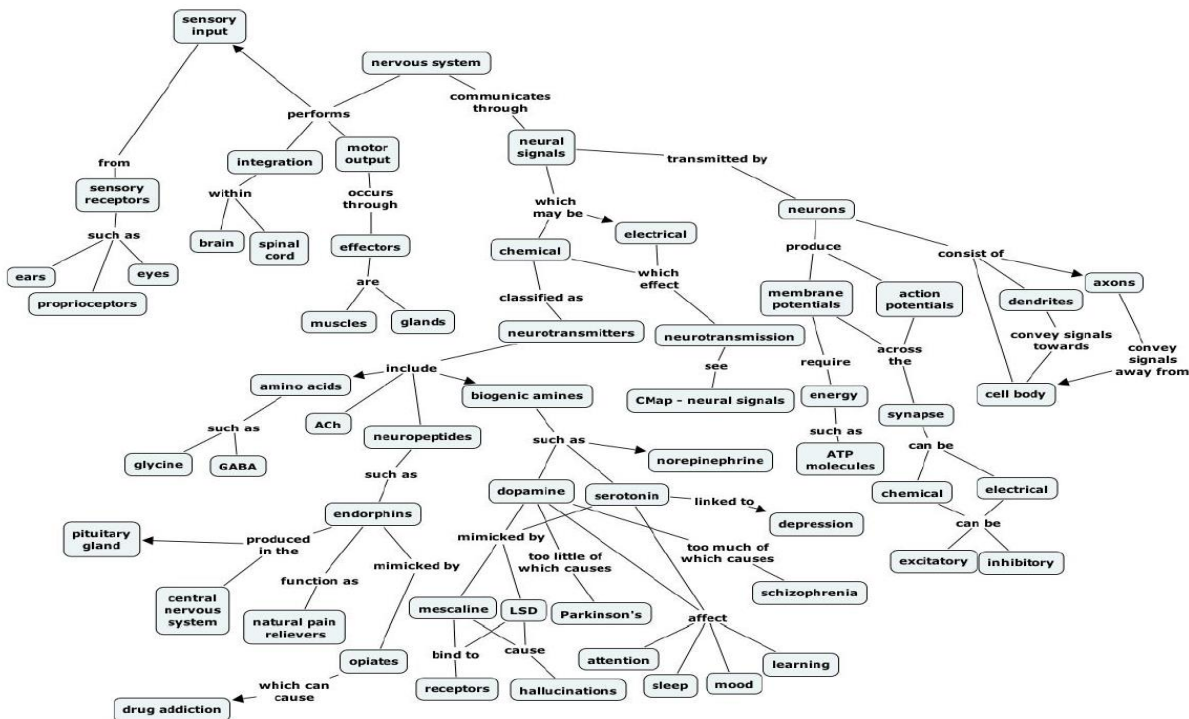


CONCEPT MAP



CONCEPT MAP EXAMPLE

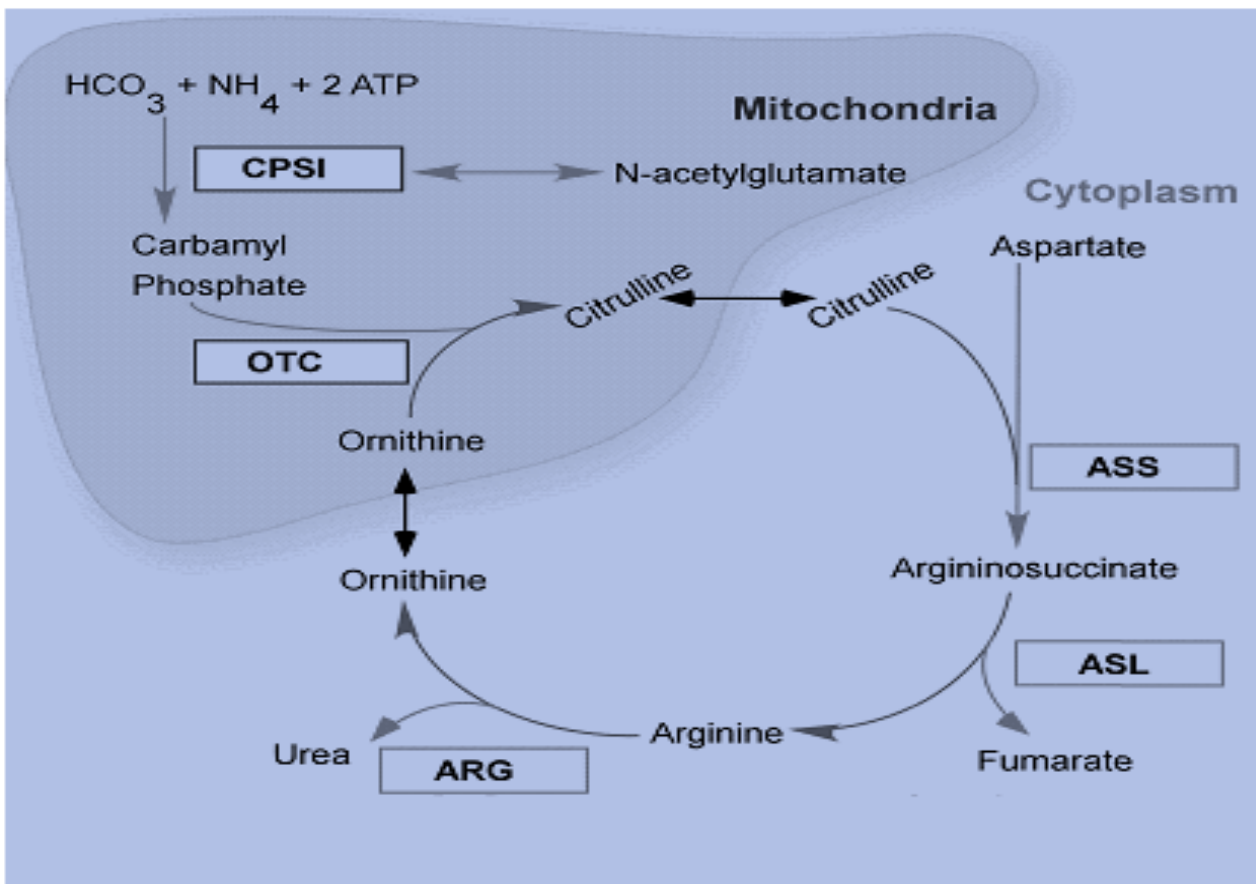


CATEGORY CHART

	PNEUMONIA	PNEUMOTHORAX	PLEURAL EFFUSION	COPD
HISTORY / INSPECTION	Cough, sputum production, fever.	Dyspnoea, chest pain, Hx of trauma. ↑JVP in tension.	Dyspnoea , mild non-productive cough, chest pain.	Chronic smoking, repeated chest infections, dyspnoea, cough.
PALPATION	<ul style="list-style-type: none"> • ↑Tactile fremitus • ↓ chest expansion - unilateral 	<ul style="list-style-type: none"> • ↓Tactile fremitus • Tracheal deviation if tension (away from affected side) • ↓ chest expansion - unilateral 	<ul style="list-style-type: none"> • ↓Tactile fremitus • Tracheal deviation (away from affected side) if >1000ml 	<ul style="list-style-type: none"> • ↓ chest expansion bilaterally
PERCUSSION	Dull	Hyper-resonant	Stony Dull	Hyper-resonant
AUSCULTATION	<ul style="list-style-type: none"> • Bronchial Breathing • Added sounds: crackles and wheeze • ↑Vocal resonance (whispering pectoriolquy) 	<ul style="list-style-type: none"> • ↓, vesicular breath sounds • Added sounds 	<ul style="list-style-type: none"> • ↓ vesicular breath sounds • Crackles at the upper edge of the effusion • Pleural friction rub • Muffled vocal resonance 	<ul style="list-style-type: none"> • ↓, vesicular breath sounds • Added sounds: wheeze, crackles

fastbleep))

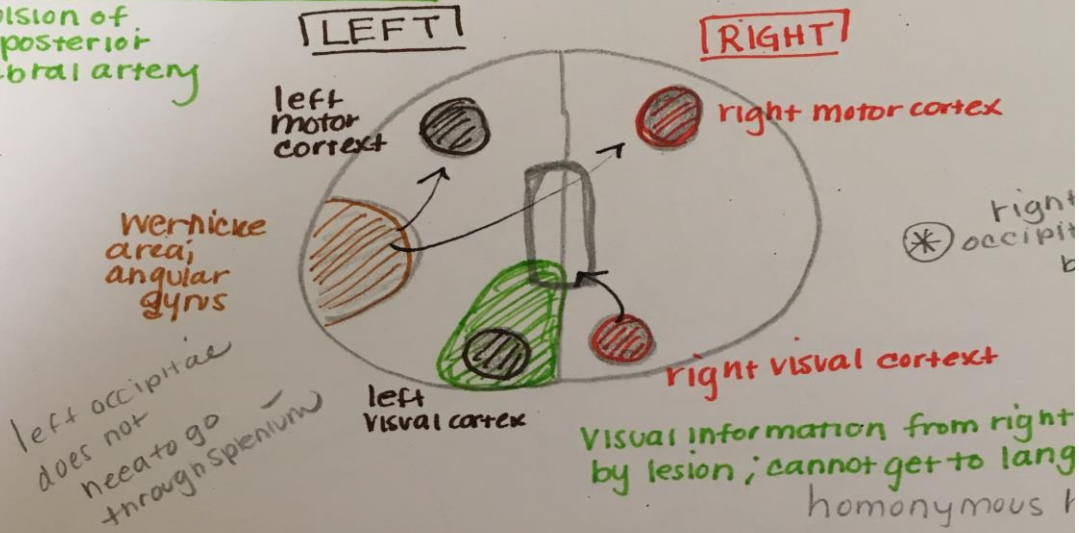
FLOW CHART



DIAGRAM

Alexia without agraphia (can write; but cannot read)

o occlusion of left posterior cerebral artery



Conduction Aphasia

arcuate fasciculus

Middle Cerebral Artery

follow your
- unable to rep

- Broken speech
- Motor/syntax
- dominant side usually left

